

# The Future of Orthopaedic Surgery and Traumatology

The last 50 years has seen spectacular advances in the scope and range of treatments in Orthopaedics and Trauma surgery particularly in techniques, applications of chemotherapy (including antibiotics) of all types and cell therapy, especially in joint cartilage repair by autografts and mesenchymal stem cells. The next 20 years will see much refinement of these advances but also a fundamental shift towards the development of cell-based therapies in the M/S system.

## 1. Hereditary diseases,

Genetic screening for congenital diseases of the M/S system will expand so that the genetics is clarified which will facilitate parental guidance and at the same time lead to control of some of the plethora of musculo-skeletal abnormalities( as yet poorly understood) by targetted gene therapy. Already research and management of diseases such as Muscular dystrophy are well advanced in this area<sup>1</sup>.

## 2. Children's disorders

- a) Universal ultrasound scanning and MRI of infants will be developed so that examination of the newborn will include assessment of the whole M/S system. Thus dysplasias of limbs and joints (especially the hip) will be recognised and treated early to prevent later disease and disability<sup>2</sup>.
- b) Spinal Deformity( Scoliosis ) is quite successfully treated by major mechanical techniques such as operative correction and rodding which corrects deformity but also stiffens the spine. It is possible to insert a rod at an early stage which will extend and correct the spine by remote impulses during growth but this is only partially successful and has some complications<sup>3</sup>.

The problem is one of abnormality of growth of the spine which could be prevented with targetted growth arrest of the growth-plates (epiphyses) at appropriate times in the child's growing period which could be achieved by robotically –controlled lasers, as in heart surgery for irregularities, thus making spinal curvature correction more precise and non-invasive.

This genetic work involves close relationships with colleagues in the basic sciences,

## 3. Development of replacement prostheses-new techniques and materials

The outstanding success of major joint replacement of the Hip and Knee for Arthritis and tumours is well established but is limited in other joints by the size of the joints, the accuracy of techniques, the durability of the materials, loosening of the implant through mechanical stresses and the ever-present (although yet small) risk of infection.

Thus some joints cannot be replaced because they are too small or inaccessible (eg .spinal joints and hand and feet joints, or because access is so difficult, or because the stresses

placed on them is so great that loosening occurs in a few years. Later failure is due to secondary infection, wear of the materials or loss of stability due to soft tissue weakness of ligaments around the implant.

In the spine of adults, exciting work on replacement of the Intervertebral discs is already occurring but is semi-experimental and better materials and fixation methods will develop which could greatly enhance the treatment of the common spinal disc problems in low back pain and sciatica<sup>4</sup>.

#### 4. Other joint and bone replacements

At present it is not possible to replace successfully the foot joints (ankle replacements are reasonably successful for up to 10 years) but only for sedentary activities because of the risk of loosening and/or failure of the materials due to wear or fatigue.

The situation is similar for the shoulder, elbow and wrist and hand.

Inevitably this situation will improve with more inert and durable materials than the present chrome-cobalt and titanium metals and Polyethylenes and more sophisticated techniques. There has been limited success with materials such as carbon fibre, titanium mesh, ceramics for surfaces and some biological materials such as collagen/hydroxyapatite replacement for bone and cartilage replacement. However, the qualities required of the materials, of bio-compatibility, strength and durability with flexibility (Different for different joints and bones) and infection resistance, are challenging.

Development of infection-resistant coatings for implants to combat the formation of "bio-films" by bacteria on the surface of the implants, looks promising (presently silver compounds) which is particularly important with implants which are expected to last potentially for 40-50 years<sup>5</sup>. Otherwise, antibiotic-resistant bacteria will almost certainly make prosthetic implantations and their revision after failures more vulnerable in future.

#### 5. Computer-guided Surgery and use of Robots for accurate positioning of prostheses is a controversial area<sup>6</sup>.

The potential value of their use is based on the fact that prostheses need to be placed accurately to take the strains of load-bearing and to give normal function, and that failure by loosening and/wear will occur more often if the joints are not precisely positioned.

Computer-guided hip and knee prostheses are in general more predictably accurately placed when guided by computer systems or (though less so) when inserted by robots compared with trained surgeons.

However, the systems need surgeons and technicians to operate them and they are generally expensive for all but major replacement units.

Furthermore, the clinical results of using computer or robots have not as yet been demonstrated to be always superior to those achieved by experienced surgeons using "state-of-the-art" regular instrument systems.

Inevitably this field will be developed and simplified, achieving superior outcomes and lower costs, within 20 years.

#### 6. Musculo-skeletal tumours are Primary or Secondary (metastases).

Primary malignant bone tumours eg, osteosarcoma, are highly malignant, locally aggressive, common in children and often metastasise. They are fatal if untreated.

It is established that early excision reduces the risk of spread and death rate but this involves amputation of the limb in 50% of cases.

A major development over the past 40 years has been the design and manufacture by computer for each individual patient (CAD/CAM-computer-aided design and computer-aided manufacture) piloted by the bio-engineering unit at Stanmore by Professors Scales, Walker and Blunn with the collaboration with the Orthopaedic surgeons at the Royal National Orthopaedic Hospital, Stanmore (Professors Bentley, Briggs and Skinner, Mr. Cannon, Miss Muirhead –Allwood, Mr Carrington<sup>7</sup>).

Nowadays it is possible to design a replacement prosthesis for all or part of a bone such as the femur or humerus incorporating replacement knee or hip joints. After meticulous surgical excision, controlled for completeness by the histopathologist, the custom-made prosthesis can be inserted into the limb, thus giving very good function and avoiding amputation.

Pre-operative chemotherapy by the oncologists to reduce the size of the tumour as much as possible before excision is designed and controlled to target the individual tumour and is continued post-surgery if required. This highly sophisticated team approach has dramatically reduced the number of amputations to 5% and survival is enhanced to 70% or more.

Although this has had a major impact on thousands of lives there is a problem that such prostheses can loosen after 10 years and replacing them, a second time, is difficult.

In future it will be possible to remove the tumour by local excisional surgery and create a replacement which is constructed of a bone graft framework with living bone precursor stem cells which will eventually incorporate to restore the bone and/or joint and avoid all the long-term problems of metallic prostheses.

In the meantime, work is in progress to improve the fixation of prostheses to bone by hydroxyapatite coatings and the use of stem cells to effect a seal between the skin and the prosthesis stem which can be a source of late infection.

Also, a recent development has been to make a “growing” prosthesis designed to be lengthened remotely as the child grows. This is extremely important to avoid the need for repeat prostheses which is necessary as some very young children grow, to keep their leg lengths equal and their function as normal as possible<sup>8</sup>.

#### 7. 3-D Printing of Prostheses<sup>9</sup>

The use of 3-D printing for production of precisely-built objects ranging from houses to industrial machines is possible for manufacture of metallic and plastic body parts. Thus whole bones or joints can be produced very cheaply although the issues of integration into the tissue by the implant and the surface contour and finish in moving joints has not been perfected.

Nevertheless the possibilities, especially for small bone and joint parts should be fulfilled in the future provided the quality and cost can be assured. It represents an exciting new technology.

#### 8. Musculo-Skeletal Imaging-Arthroscopy and Fluoroscopy, C T Scanning and reconstruction, MRI<sup>10</sup>.

Arthroscopy is now possible for visualising the interior of the knee, shoulder, the hip, wrist, elbow and ankle and even the interior of tendon sheaths.

The most important application of arthroscopy and X-ray fluoroscopy is to facilitate and make possible surgical procedures using extremely ingenious instruments by only a tiny incision.

The surgeon is able to visualise exactly the field he/she is operating on and place implants, plates, screws, nails, pins, joint anchors, etc. precisely which is vital for optimal function.

The modern sterile air operating theatre is now a surgical laboratory where all forms of imaging can be employed to guide the majority of bone and joint procedures.

This is very important for surgical training because the images can be seen outside the theatre as well as within so that remote supervision of one or several trainees is possible making personal Consultant supervision a reality in all cases.

This scenario is everyday practice in the most advanced specialist units and has the great advantage of very rapid rehabilitation with very low complication rates, especially infection.

Arthroscopy - fluoroscopy will continue to be important in reducing morbidity for the patients and also cost in a wider range of joints and Orthopaedic units.

Of course other forms of Imaging in addition to routine X-Rays, such as MRI (Magnetic Resonance Imaging) for soft-tissue diseases and ligament injuries, spinal Intervertebral prolapse, tumours and infections give greatly enhanced accuracy in defining the extent of

soft tissue damage. This can define the precise size and location of tumours, infections (osteomyelitis) and major ligamentous injuries.

Computerised tomography (CT) scanning is able to reconstruct complex fractures in, eg, the pelvis, in areas which cannot be seen by any other means. This is vital in complex life-threatening situations of massive bleeding and can guide either intravenous or open surgical closure of blood vessels which is life-saving.

This technology will be increasingly applicable in other areas of the skeleton after major trauma in future.

Most of the present and future imaging is controlled by specially trained Radiologists but the scope of this can be expanded by training also of expert technicians.

Funds for the equipment and infrastructure for Musculo-skeletal imaging will prove highly cost-effective as the applications simplify the manufacturing and staff costs which will be offset by increase in high quality results, reduction of disability, a rapid return to function and employment.

#### 9. Cell-Based Therapy in Orthopaedics (Autologous Chondrocyte Transplantation and Stem cell transplantation)

This field has developed in the last 2 decades and was pioneered by Professor Bentley, by international collaboration between the Orthopaedic departments of the Universities of Pittsburgh, Liverpool, Oxford and UCL/Stanmore for treatment of joint articular cartilage injuries and early Osteoarthritis. Early work on the use of cell-therapy for established Osteoarthritis (which affects 40% of the population over age 50 of whom approximately 50% require surgical treatment), is in progress in the U.K., USA, Europe and Sweden.

Since the original experiments, the present situation is that injuries to articular cartilage in the knee, which without treatment progress to produce early-onset osteoarthritis because of the inability of the bone beneath the cartilage to produce normal type II collagen unique to articular cartilage, can be repaired and cartilage regenerated in 70% to 80% of patients. This is achieved by transplantation of Autologous Chondrocytes taken from the patient by arthroscopy, cultured in the laboratory for several weeks, and then transplanted into the damaged area.

This restores function and relieves pain and delays, if not preventing completely, the onset of Osteoarthritis in 70% of young patients (range 15 to 50 years).

This technique has been applied to human joints for 20 years in various centres in the world and has been accepted, after clinical trials, as recently recommended by NICE as applicable and cost-effective<sup>11,12,13,14</sup>.

The technique is a 2 stage procedure to remove a small fragment of articular cartilage from the affected joint from which the chondrocytes, which produce the glycosaminoglycans and type II collagen matrix(unique to articular Cartilage) are released in a viable state by the modified technique of Audrey Smith(MRC Scientist )of enzymatic dissolution of the matrix.

Freed from their matrix, the cells multiply in culture by 30 to 40 times in 4 weeks to give approximately 100,000 living cells.

These are then concentrated by centrifugation,and re-implanted into the prepared cartilage(and sometimes bone) defect,and held in place by a typeI/III collagen membrane.Mobilisation and walking on the knee is commenced after 48 hours and full mobilisation achieved after 3 to 6 months.

MRI scanning is used to monitor the graft and, if incorporation is achieved on scanning, full activity can begin after 6 to 12 months,depending on patient comfort.

Previous histological studies of the grafts have shown the formation of hyaline cartilage (containing type II collagen) after 2 years.

The significance of this method is that it relieves symptoms and restores function in these young patients for up to 20 years and delays the onset of “early onset” osteoarthritis<sup>12,15</sup>.

The progression to using this for OA in older patients has started and early results are promising<sup>16</sup>.

It has been shown that the OA joint contains debris and cytokines produced by the inflammation of the joint lining synovial membrane which are toxic to cartilage cells so that a race is present between these agents and the healing cells.Also, it is necessary to correct any mechanical deformity in the joint which would cause excessive pressure on the repairing tissue.Early work suggests that control of these cytokines is possible and surgical correction of alignment of the knee is possible already.

Thus the exciting prospect ,of treating advanced OA by cell therapy which could restore normal joints, is opened up for the next 20 years.

#### 10.Stem cell repair and regeneration of joint cartilage injuries and osteoarthritis

Recently, Autologous Mesenchymal stem cells(M.S.C's) have been considered as a possible cell source for joint repair which are easy to acquire from the patient and can be taken from the bone marrow of the pelvis and transferred to the damaged knee cartilage surface with the patient requiring only one procedure,anaesthetic etc.(Figure 1).

Moreover, the progress of the healing of the graft can be monitored non-invasively by MRI thus indicating when it is ready to take up full load and activity after operation,which can be as early as 6 months post-operatively.

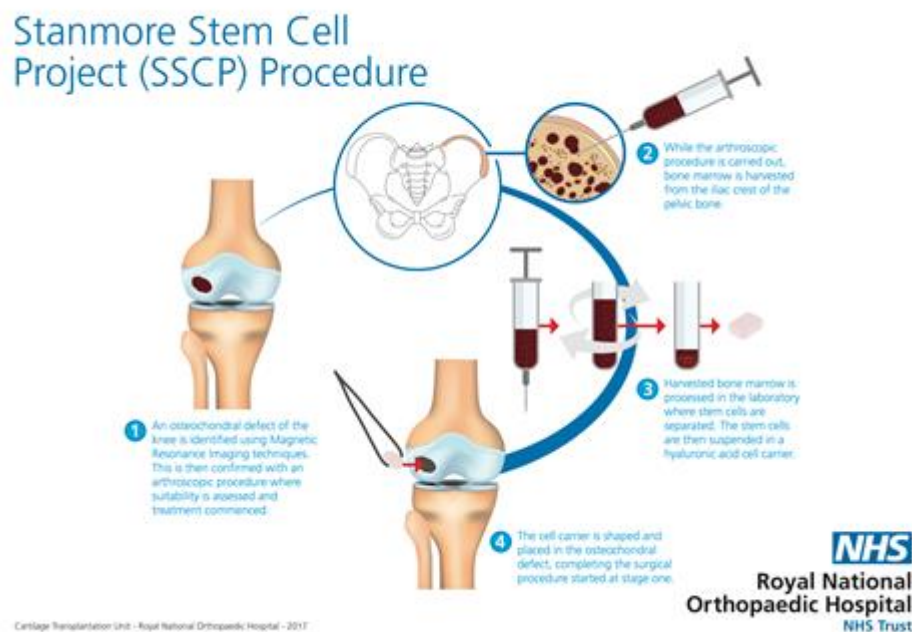
The procedure, at present undergoing trials at Stanmore and other centres is showing promising repair on MRI after 12 months.

If the study proves effective it can be applied to other joints, with very considerable benefits to patients.

Moreover, it is a less complicated and cost-effective method than our previous ACI/MACI chondrocyte method described above.

Strict randomised studies over at least 5-10 years are needed to validate this much simplified and economical method.

Figure 1 – Diagrammatic representation of the Stanmore Stem Cell Project (SSCP) procedure for implantation of Mesenchymal Stem Cells (M.S.C's) from the bone marrow of the pelvis into the articular cartilage defect in the knee.



## References

1. **Editorial – the BMJ**. 10 February, 2018. "Nucleic acid based therapies: frontier for precision medicine". Pirmohamed M.
2. November 21, 2016 **Report recommends changes in screening for developmental dysplasia of the hip** Brian A. Shaw, M.D., FAAOS, FAAP and Lee S. Segal, M.D., FAAP
3. "Surgical results of **magnet driven growing rods (MdGR)** for early-onset **scoliosis (EOS)**: Single center experience of five years". Spine Deformity. 2015;3:622. ... The effect of magnetically controlled **growing rod**. Harshavardhana NS, Fahmy A, Noordeen H.

4. "Applications of lumbar Spinal Fusion and Disc replacement" R.W. Marshall and Neta Raz  
*In "European Orthopaedics and Traumatology"*, Ed. Bentley,G: 2014. *Springer Reference*,Vol.2,581-608
5. [Int J Mol Sci](#). 2014 Jul 4;15(7):11878-921. doi: 10.3390/ijms150711878.  
"Implant coatings:Bioactive coatings for orthopaedic implants-recent trends in development"  
[Zhang BG](#)<sup>1</sup>, [Myers DE](#)<sup>2</sup>, [Wallace GG](#)<sup>3</sup>, [Brandt M](#)<sup>4</sup>, [Choong PF](#)<sup>5</sup>.  
[J Arthroplasty](#). 2018 Jan 31. pii: S0883-5403(18)30065-2. doi: 10.1016/j.arth.2018.01.027. [Epub ahead of print]
6. "Current Role of Computer Navigation in Total Knee Arthroplasty".[Jones CW](#)<sup>1</sup>, [Jerabek SA](#)<sup>1</sup>  
[J Arthroplasty](#). 2018 Jan 31. pii: S0883-5403(18)30065-2. doi: 10.1016/j.arth.2018.01.027. [Epub ahead of print]
7. "Versatility – a major advantage of custom CAD-CAM uncemented HA-coated hip replacements"  
Walker PS, Muirhead-Allwood W, McCullough CJ, Bentley G, Cobb AG, Caterall A, Hua J,Dabestani M.  
*J.Bone Joint Surg(Br)*.1995,vol 77,101.
- 8."Stanmore Custom-made extendible distal femoral replacements"  
Schindler OS, Cannon SR, Briggs TWR, Blunn GW.  
*J.Bone Joint Surg*.1997,Vol 79-B,No.6.p 927.
- 9." Use of 3D printing in orthopaedic surgery" Mackinnon J, Jasvinder Kashif ,*BMJ* 2014; 348  
doi: <https://doi.org/10.1136/bmj.g2963> (Published 08 May 2014) .
10. "Musculo-Skeletal Imaging" Tyler P and Saifuddin A. *in " European Surgical Orthopaedics and Traumatology"*,ed.Bentley G, *Springer reference*,2014.
- 11."Homotransplantation of isolated epiphyseal and articular chondrocytes into joint surfaces".Bentley G and Greer RB.*Nature*. 1971. Vol 230,5293,385-391
12. "A 10 year review of a randomized comparison of ACI and Mosaicplasty for the treatment of osteochondral defects in the knee".Bentley G,Biant L,Vijayan S, Skinner JA Carrington RC. *J Bone Joint Surg*.2012,94B;No 4.504-509,
- 13."A 2 to 12 –year follow-up of ACI versus MACI for the treatment of osteochondral defects in the knee".Nawaz SZ,Bentley G,Briggs TWR,Carrington R,Skinner JA, ***J.Bone and Joint Surg[Am]*. 2014,May 21;96(10);824-30.**
- 14.NICE Guidelines ,TA 477-October 2017-Treatment of articular defects of the knee by Autologous Chondrocyte Implantation(ACI)—*see "Indications for ACI"*.
- 15.Brittberg M,Lindahl A,Nielsson A,Ohlsson C,Isaksson O,Petersen L."Treatment of deep cartilage defects in the knee with autologous chondrocyte transplantation".*N Eng J Med*,1994,Oct 6;331,(14)889-95.



16. Minas T et.al."Autologous Chondrocyte Implantation for joint preservation in patients with early Osteoarthritis".Clin Orthop Rel Res. 2010 Jan :468(1),147-157.



Professor George Bentley, M.B., Ch.B., ECFMG(USA), D.Sc., Ch.M., FRCS., FRCS(E)., F.Med.Sci.  
Emeritus Professor and Director, Institute of Orthopaedics and Musculo-Skeletal Science,  
U.C.L., London,  
Honorary Consultant Orthopaedic Surgeon,  
Royal National orthopaedic Hospital, Stanmore,  
Lead Investigator, Stanmore Stem Cell Project(SSCP).

1. **H  
o  
m  
o  
t  
r  
a  
n  
s  
p  
l  
a  
n**

Stanm  
Project

**t  
a  
t  
i  
o  
n  
  
o  
f  
  
i  
s  
o  
l  
a  
t  
e  
d**

Cartilage Transplantation

1. **H  
o  
m  
o  
t  
r  
a  
n  
s  
p  
l  
a  
n**

Stanm  
Project

**t  
a  
t  
i  
o  
n  
  
o  
f  
  
i  
s  
o  
l  
a  
t  
e  
d**

Cartilage Transplantation

1.